

# Effect of adipose-derived nucleated cell fractions on tendon repair in horses with collagenase-induced tendinitis

Alan J. Nixon, BVSc, MS; Linda A. Dahlgren, DVM, PhD; Jennifer L. Haupt, BS; Amy E. Yeager, DVM; Daniel L. Ward, PhD

**Objective**—To assess the potential of adipose-derived nucleated cell (ADNC) fractions to improve tendon repair in horses with collagenase-induced tendinitis.

**Animals**—8 horses.

**Procedures**—Collagenase was used to induce tendinitis in the superficial digital flexor tendon of 1 forelimb in each horse. Four horses were treated by injection of autogenous ADNC fractions, and 4 control horses were injected with PBS solution. Healing was compared by weekly ultrasonographic evaluation. Horses were euthanized at 6 weeks. Gross and histologic evaluation of tendon structure, fiber alignment, and collagen typing were used to define tendon architecture. Biochemical and molecular analyses of collagen, DNA, and proteoglycan and gene expression of collagen type I and type III, decorin, cartilage oligomeric matrix protein (COMP), and insulin-like growth factor-I were performed.

**Results**—Ultrasonography revealed no difference in rate or quality of repair between groups. Histologic evaluation revealed a significant improvement in tendon fiber architecture; reductions in vascularity, inflammatory cell infiltrate, and collagen type III formation; and improvements in tendon fiber density and alignment in ADNC-treated tendons. Repair sites did not differ in DNA, proteoglycan, or total collagen content. Gene expression of collagen type I and type III in treated and control tendons were similar. Gene expression of COMP was significantly increased in ADNC-injected tendons.

**Conclusions and Clinical Relevance**—ADNC injection improved tendon organization in treated tendons. Although biochemical and molecular differences were less profound, tendons appeared architecturally improved after ADNC injection, which was corroborated by improved tendon COMP expression. Use of ADNC in horses with tendinitis appears warranted. (*Am J Vet Res* 2008;69:928–937)

Tendinitis of the digital flexor tendons remains a catastrophic condition in all types of sport horses. Racing statistics indicate tendinitis is the most frequent cause of breakdown and is often a career-ending event in Thoroughbreds.<sup>1,2</sup> Injuries to the SDFT alone account for an estimated 8% to 30% of all racing injuries.<sup>3–5,a</sup> Moreover, recurrence of tendinitis after return to competition can be as high as 43%.<sup>6,7</sup> These issues have been recognized for many years, yet few major advances in treatment have improved the proportion of horses that resume sustained racing.

Received July 31, 2007.

Accepted November 15, 2007.

From the Comparative Orthopaedics Laboratory, Department of Clinical Sciences, College of Veterinary Medicine, Cornell University, Ithaca, NY 14853-6401 (Nixon, Dahlgren, Haupt, Yeager); and the Veterinary Medicine Experiment Station, Virginia-Maryland Regional College of Veterinary Medicine, Virginia Polytechnic Institute and State University, Blacksburg, VA 24061 (Ward). Dr. Dahlgren's present address is the Department of Large Animal Clinical Sciences, Virginia-Maryland Regional College of Veterinary Medicine, Virginia Polytechnic Institute and State University, Blacksburg, VA 24061.

Supported in part by Vet-Stem Incorporated.

The authors thank Mary Lou Norman for assistance with histologic preparation of tissues.

Address correspondence to Dr. Nixon.

## ABBREVIATIONS

ADNC	Adipose-derived nucleated cell
COMP	Cartilage oligomeric matrix protein
IGF-1	Insulin-like growth factor-1
MSC	Mesenchymal stem cell
SDFT	Superficial digital flexor tendon

Traditional modes of treatment for tendinitis have included medical and surgical options.<sup>7–14</sup> Most treatment modalities attempt to decrease inflammation within the tendon, prevent further trauma to damaged tissues, stimulate the healing process, and prevent recurrence of the injury after the horse resumes training. Regardless of the type of treatment selected (ie, medical or surgical), extended rest with gradual increases in controlled exercise has been the cornerstone for a successful outcome.<sup>14–16</sup> Retrospective studies<sup>2,17</sup> have revealed that approximately 40% to 60% of injured horses return to athletic soundness for at least a short period after injury of the SDFT; however, recurrence of injury is common.

High rates of tendon reinjury have stimulated investigations of methods for modulating tendon healing that provide better repair consistent with the original tendon architecture.<sup>2,9,11,13,18</sup> Cells, growth

factors, and scaffolds to support mixtures of these components have been described. Adult tissue-derived stem cells have emerged as injectable potentially multipotent cells that have the capability of differentiating and participating in the healing of various musculoskeletal tissues, including tendon.<sup>19-29</sup> In adults, these multipotent cells originate from numerous mesenchymal tissues, such as bone marrow, perivascular tissues, blood, tendon, muscle, and adipose tissue,<sup>30,31</sup> all of which can be used as a source of autogenous multipotent cells for transplantation. Mesenchymal stem cells were identified in bone marrow stroma > 25 years ago<sup>32</sup>; however, potential drawbacks to the use of bone marrow aspirates to provide a pool of MSCs for therapeutic purposes have included pain associated with the collection process, low cell yield, and pericardial laceration during collection of sternal bone marrow.<sup>33,34</sup> Additionally, bone marrow-derived MSCs require several weeks of culture after marrow harvest until they are available as a substantial pool of cells for reimplantation.<sup>35</sup>

Adipose tissue can be harvested from several sites in horses, including pericoccygeal, sternal, and inguinal fat depots. Coccygeal fat at the base of the tail represents the most accessible site in standing horses and can be surgically excised in horses administered sedatives and local anesthesia. Isolation of the nucleated cell fraction from fat provides a pool of cells for immediate injection into sites of injury or for use in further culture propagation to yield isolated adipose-derived stem cells. The value of ADNC fractions or adipose-derived multipotent stem cell cultures for repair of acute and subacute tendinitis and suspensory desmitis are largely unknown.

Mesenchymal stem cells derived from equine bone marrow have been evaluated experimentally for cartilage repair in horses<sup>36</sup> and for treatment of a clinically affected horse with tearing of the SDFT.<sup>22</sup> These reports support the use of multipotent cells in repair of connective tissue diseases in horses. Treatment with immediate reinjection of bone marrow aspirates have been used for adult horses with tendon and ligament injuries (chronic suspensory disease) for many years.<sup>37</sup> In reality, bone marrow aspirates contain few stem cells and these are extensively diluted by the large volume of bone marrow-derived blood. Culture expansion increases the number of stem cells available for injection<sup>22,35,38</sup>; however, this technique requires a delay of several weeks. Adipose tissue provides an alternative source of multipotent cells for culture expansion but may also provide benefit in the form of concentrated nucleated cell populations, many of which may be clinically relevant when compared with bone marrow.<sup>39,40</sup> Overnight digestion, separation, and concentration of the nucleated cell content in fat provides an injectable source of potentially stimulatory cells. However, the effectiveness of concentrated nucleated cells prepared by digestion and centrifugation, compared with the effectiveness for cultured multipotent stem cells, is unknown.

Adult-derived stem cells can participate in the regeneration of damaged tissues via 2 distinct mechanisms. Direct contribution through differentiation into tissue-specific cell phenotypes and the production of tissue-appropriate extracellular matrix products is obvious. To this end, adipose-derived adult stem cells

have the capability of differentiating into osteoblasts, myoblasts, chondroblasts, and tenocytes *in vitro*<sup>24,30,41</sup> and *in vivo*.<sup>42,43</sup> Potentially of equal importance, adult tissue-derived stem cells contribute to tissue healing indirectly through the production of bioactive proteins, such as growth factors, antiapoptotic factors, and chemotactic agents.<sup>44</sup> These secreted proteins have a profound effect on local cellular dynamics, stimulation of vascular ingrowth, and recruitment of additional adult stem cells capable of further stimulation of healing.

The objective of the study reported here was to evaluate the short-term efficacy of ADNC fractions for the treatment of horses with tendinitis. Collagenase was used to induce tendinitis of the SDFT. Clinical, ultrasonographic, morphologic, biochemical, and gene expression effects of ADNC injection were compared with results for vehicle-injected control tendons. The hypothesis was that intralesional injection of ADNC fractions would improve healing of tendon core lesions through an increase in cell numbers, reduction of tendon inflammation, and increases in collagen and other matrix components, which would lead to improved tissue architecture in repaired tendon.

## Materials and Methods

**Animals**—Eight clinically normal young adult (2 to 6 years old) horses of various breeds were used in the study. Horses were examined clinically and ultrasonographically to ensure there was no preexisting tendon damage. The project was approved by the Cornell University Institutional Animal Care and Use Committee.

**Induction of tendinitis**—Tendinitis was induced in the midmetacarpal region of the SDFT of 1 randomly selected forelimb of each horse. Tendinitis was induced by use of a method described and characterized elsewhere.<sup>45-51</sup> Each horse was medicated with NSAIDs before injections to induce tendinitis. Regional nerve blocks were used for pain management, and local anesthesia of the skin allowed precise administration of collagenase. Filter-sterilized bacterial collagenase type I<sup>b</sup> diluted in sterile water was prepared, and a small volume (0.3 mL) containing 2,097 units of collagenase was divided equally and injected into 2 sites in the center of the SDFT approximately 2 cm apart. Collagenase was injected 13 and 15 cm distal to the accessory carpal bone. The injected limb was supported by application of a sterile bandage, and each horse was confined to a stall without exercise for the initial 4 weeks after collagenase injection.

**Ultrasonographic examinations**—Development of a focal tendinitis core lesion was monitored by use of repeated ultrasonographic examinations. Ultrasonography was also performed weekly after ADNC injection. Ultrasonographic examinations with a 12- to 15-MHz, 38-mm linear probe<sup>c</sup> were performed in transverse and longitudinal planes to evaluate the SDFT. Measured variables were derived from cross-sectional images obtained 15 and 18 cm distal to the accessory carpal bone. Cross-sectional area of the tendon core lesion and cross-sectional area of the total tendon were assessed. Echoic characteristics of the core lesion on transverse images and the linear fiber pattern on longitudinal im-

ages were graded.<sup>52</sup> Lesion grade was scored on a scale from 1 (normal tendon) to 4 (extensive damage), and linear fiber pattern was graded on a scale from 1 to 4 (1 = loss of 0% to 25%, 2 = loss of > 25% to 50%, 3 = loss of > 50% to 75%, and 4 = loss of > 75% to 100%).

**Collection of adipose tissue and preparation of ADNC fractions**—Formation of tendinitis core lesions was verified ultrasonographically 4 days after collagenase injection. On day 5 after collagenase injection, adipose tissue was harvested. Adipose tissue harvest and ADNC preparation were performed for all horses to ensure investigators remained unaware of treatments for each horse.

Horses were sedated, the paraxial caudodorsal gluteal region was clipped, and the skin was aseptically prepared. An inverted L pattern of local anesthetic infiltration was used for regional desensitization. A linear incision 10 to 15 cm in length was made approximately 10 cm abaxial and 10 cm cranial to the tail head; the incision was centered in the groove formed by the proximal origin of the biceps femoris and semitendinosus muscles. Approximately 15 to 20 g of subcutaneous adipose tissue was dissected by use of curved scissors. The adipose tissue specimen was placed in a 50-mL polypropylene centrifuge tube containing sterile PBS solution and maintained at 4°C. The skin incision was closed with 0 polypropylene in a simple interrupted or Ford interlocking suture pattern. Adipose tissue was harvested from 1 site of 4 horses and 2 sites (second specimen was from an additional identical site in the contralateral gluteal region) of 4 horses. All horses received NSAIDs for 3 days after harvest of adipose tissue.

Harvested adipose tissue was shipped chilled by overnight courier to a commercial laboratory<sup>d</sup> for isolation of nucleated cells. Collagenase digestion (0.1% in Dulbecco minimal essential medium) achieved by incubation for 50 minutes and concentrating of cells by serial centrifugation were performed by use of modifications of techniques described elsewhere.<sup>40,53</sup> After isolation and purification, the ADNC pellet was resuspended in sterile PBS solution as 0.6-mL aliquots, each of which was loaded into 3 sterile syringes labeled with the date and the identification of the donor horse. Additionally, a similar number of syringes were loaded with PBS solution and labeled with the date and syringe contents. The investigator who injected the horses was not aware of the contents of the syringes. The syringes containing PBS solution and ADNC fractions were shipped chilled overnight to the investigators for immediate injection.

**ADNC injection**—The 8 horses were randomly assigned to an ADNC-treated group and a control group (4 horses/group). Power analysis was used to establish the number of horses on the basis of the coefficient of variation for biochemical assays of tendon samples from other experiments<sup>50,51</sup> in which the same collagenase technique was used. Significance (probability of type I error) was set at 5% ( $\alpha = 0.05$ ), and power analysis was used to calculate a sample size that minimized the probability of a type II error to  $\leq 15\%$  (ie, maximized the statistical power to  $\geq 85\%$ ). The operating characteristic was iteratively calculated by use of the following equation:  $\phi^2 = n\Sigma\alpha\delta^2/a\sigma^2 = (n/a) \times (\Sigma\delta^2/\sigma^2)$ , where  $\phi^2$  is the operating characteristic,  $a$  is the number of

main treatments ( $a = 2$  [ADNC and PBS solution]),  $n$  is the sample size per group, and  $\Sigma\delta^2/\sigma^2$  is the ratio of the sum of squares of the treatment effect to the variance determined on the basis of other studies with this technique. The equation was solved for sample size by use of operating characteristic curves. Power analysis was based on the SD of collagen, DNA, and proteoglycan values of 12.2% to 29.2% that have been reported in other studies, which resulted in an approximate mean SD = 17.7% and  $\Sigma\delta^2/\sigma^2 = 1.0^2/0.177^2 = 31.92$ ; hence,  $\phi^2 = 15.96 \times n$ . A sample size of 4 horses/group yielded  $\phi = 7.9$  for a statistical power of > 95%. Similar analyses for collagen response genes yielded power values of  $\geq 90\%$ .

Two days after harvest of adipose tissue (ie, 7 days after collagenase injection), the midmetacarpal area over the tendinitis core lesion was prepared aseptically for injection. Three 22-gauge needles were inserted in each horse. Ultrasonographic guidance was used to ensure needles entered the core lesion from the lateral aspect of the SDFT. Needles were inserted approximately 1 cm apart starting 15 cm distal to the accessory carpal bone and progressing in a distal direction. The 0.6-mL contents of each syringe (ADNCs or PBS solution for ADNC-treated and control groups, respectively) were injected into the center of each tendon. The same investigator performed all intratendinous injections. A sterile bandage was then applied. Day of injection of ADNCs or PBS solution was designated as day 0.

**Collection of tendon specimens**—At the completion of the 6-week study, horses were euthanized by administration of a barbiturate overdose. The SDFT from the carpus to the proximal reflection of the digital sheath was harvested by use of RNase-free conditions and stored on ice for immediate dissection. In the injected tendons, the region from 13 to 18 cm distal to the accessory carpal bone was isolated from the remainder of the SDFT; the central region was then further trimmed, and the cross-section was photographed. The affected portion of the tendon was then divided on the midline to provide a longitudinal sagittal block of tissue for histologic examination. Longitudinal tissue sections were harvested from the axial portion of the tendon, and the remaining portions of the lesion were allocated equally as diced fragments for biochemical and gene expression assays. Samples for histologic examination were fixed in 4% paraformaldehyde at 4°C. Diced samples for gene expression assays were snap-frozen in liquid nitrogen and stored at  $-80^\circ\text{C}$  until processed, whereas diced samples for biochemical analysis were rinsed in protease inhibitors<sup>e</sup> and snap-frozen in liquid nitrogen.

**Histologic examination**—Paraformaldehyde-fixed longitudinal tissue segments were dehydrated, cleared in xylene, infiltrated with paraffin, sectioned at a thickness of 6  $\mu\text{m}$ , and mounted on microscope slides. Tissue morphologic characteristics were examined on H&E-stained sections, and collagen architecture was examined by use of polarized light microscopy on sections stained with picrosirius red F3B. A composite score of 2 investigators was assigned by use of a scale of 1 (normal tissue) to 4 (severe changes) for each histologic variable (**Appendix**). A cumulative score was obtained for each horse by summing the score for each variable.

Tissue location of mRNA expression for collagen types I and III was performed by in situ hybridization with equine-specific sequences corresponding to the 5' regions for equine collagen type I and type III.<sup>50</sup> The [<sup>35</sup>S]-uridine triphosphate-labeled sense and antisense probes were synthesized, applied to serial tissue sections on glass slides, and incubated overnight in humidified chambers at 43°C, as described elsewhere.<sup>50</sup> Slides were then washed repeatedly, dried, and coated with photographic film emulsion<sup>f</sup> for autoradiography. Slides were developed after 10 to 21 days and counterstained with hematoxylin. Location of gene expression was assessed and scored on the basis of defined criteria (Appendix). Similarly, IGF-I expression in tissue sections was identified by use of riboprobes targeting the 5' region of equine IGF-I.<sup>50</sup> Scores for IGF-I gene expression were assigned from 1 (> 90% tenocytes expressing IGF-I mRNA) to 4 (< 10% tenocytes expressing IGF-I mRNA).

Immunohistochemical analysis was used to assess formation of collagen type I and type III proteins in tissue sections. Primary antibodies were generated in the Comparative Orthopaedics Laboratory at Cornell University (collagen type I) or were purchased from commercial vendors (collagen type III).<sup>g</sup> Non-immune serum and secondary biotinylated antibody were obtained from relevant species to allow binding to the primary antibody. This was followed by the use of streptavidin-conjugated peroxidase to catalyze color production from the chromogen diaminobenzidine tetrachloride, and sections were then counterstained with hematoxylin. Abundance and intensity of immunoreaction were graded on a scale of 1 to 4 (Appendix). Negative procedural control samples consisting of serial tendon sections were included on each slide, except the primary antibody was replaced by nonimmune serum. Positive and negative tissue control samples consisting of sections of normal tendon, articular cartilage, and neonatal costochondral junctions were incubated with collagen type I or type III primary antibodies.

**Gene expression**—Tendon specimens for gene expression assays were pulverized in a freezer mill<sup>h</sup> with liquid nitrogen. Pulverized tendon was then homogenized, and total RNA was extracted by use of the guanidinium chloride-phenol extraction process<sup>i</sup>; total RNA was purified by use of an affinity column.<sup>j</sup> Purity and concentration of RNA were assessed by agarose gel electrophoresis and UV spectrophotometry at 260 and 280 nm. A fluorescence-based real-time quantitative PCR assay<sup>k</sup> was used to determine gene expression for collagen types I and III, decorin, and COMP by use of primers and dual-labeled fluorescent probes generated on the basis of published equine sequences and designed with a commercially available software program.<sup>l</sup> Equine sequences for the primer and probe sets and their use in quantitative PCR assays with an absolute copy number derived from a standard curve have been described in other studies<sup>49,50,54,55</sup> conducted by our laboratory group. Total copy number for mRNA of each horse was standardized on the basis of the total RNA loaded and to expression of 18S ribosomal RNA used as a housekeeping gene.

**Biochemical analysis**—Frozen tendon specimens that had been immersed in protease inhibitors were

pulverized in liquid nitrogen and lyophilized. Ten milligrams of lyophilized tissue was digested by incubation in 0.5% papain<sup>b</sup> for 4 hours at 65°C, and the glycosaminoglycan content was then determined by use of the dimethylmethylene blue dye-binding assay.<sup>56</sup> Residual papain digest was incubated for another 20 hours at 65°C, and DNA concentrations were then quantified by use of the bisbenzimidazole fluorometric assay.<sup>57</sup>

Concentrations of soluble collagen were measured by use of the picosirius red F3B dye-binding method.<sup>m</sup> Pulverized, lyophilized tissue samples were weighed; resuspended in lysis buffer that contained detergent,<sup>n</sup> protease inhibitors, and glycerol; homogenized; and centrifuged at 15,000 × g for 10 minutes. The precipitate was digested by incubation in acid-pepsin at 4°C overnight with stirring, which was followed by centrifugation at 30,000 × g for 45 minutes. Supernatant was harvested and used for the dye-binding spectrophotometric assay. Values were standardized on the basis of the number of milligrams in the dry weight of the original tissue specimen.

**Statistical analysis**—Quantitative data from biochemical and molecular gene expression analyses for ADNC-treated and control tendons were compared by use of the Student *t* test. Histologic scores were compared by use of the Wilcoxon rank sum test. To examine changes in ultrasonographic cross-sectional area attributable to treatment and over time, a repeated-measures ANOVA was conducted to test the main effects of treatment and time and the treatment-by-time interaction. For each response variable, values recorded before administration of treatment were included in the model as a covariant. Significance was set at values of  $P \leq 0.05$ .

## Results

**ADNC preparation and injection**—Adipose tissue was successfully harvested from all horses. Two sites were required in 4 lean horses to obtain 20 g of tissue. Skin incisions healed without complication in all horses except one, which developed a seroma with subsequent dehiscence; the wound in that horse was allowed to heal by second intention.

Yield of ADNCs ranged from  $1.47 \times 10^6$  cells/g to  $2.71 \times 10^6$  cells/g (mean  $\pm$  SD,  $2.30 \pm 0.57 \times 10^6$  cells/g). Cell viability after overnight digestion ranged from 83% to 91% (mean, 87.5%).

Tendon injection of ADNCs or PBS solution was readily accomplished, and there were no adverse effects that resulted from the injection. Cell viability at time of injection was not determined. Range of elapsed time from harvest of adipose tissue to injection of ADNCs was 40 to 53 hours. Each horse received the 3-syringe series (0.6 mL/syringe). Mean  $\pm$  SD number of ADNCs in each syringe was  $13.83 \pm 3.41 \times 10^6$  cells.

**Clinical evaluation**—Collagenase-induced disruption of tendon fibers developed within 5 days after collagenase injection. Persistent enlargement of the SDFT in the midmetacarpal region was visible throughout the 6-week study. There were no apparent clinical differences in the degree of swelling between the affected limbs in the 2 groups of horses.

**Gross morphologic characteristics**—Surface epitenon layers of ADNC-treated tendons appeared less hemorrhagic and had a smoother surface, compared with the appearance of control tendons (Figure 1). Examination of transverse sections revealed the site of tendinitis, which varied from brownish to reddish. There were no differences of color in transverse sections between the 2 treatment groups.

**Ultrasonographic examination**—Quantitative analysis of tendon ultrasonographic images revealed no differences between the 2 groups during the period preceding ADNC or PBS solution injection or throughout the 6 weeks after ADNC or PBS solution injection (Figure 2). Scores for linear fiber pattern improved in both groups during the course of the study. Scores for linear fiber pattern were initially higher (more deranged) in the ADNC-treated group, but improved to become lower than scores for the control group at 35 and 42 days after injection. Similarly, ADNC-treated tendons revealed improvement on the basis of lesion grades for days 14 through 42 after injection.

**Histologic examination**—Longitudinal sections stained with H&E and picosirius red were analyzed and scored. Normal tendon had a perfect score of 13, and maximally damaged tendon had a score of 52. Mean  $\pm$  SD overall healing score for ADNC-treated horses ( $24.8 \pm 2.1$ ) was significantly ( $P = 0.029$ ) better, compared with the overall score for PBS solution-treated horses ( $33.5 \pm 2.8$ ). In general, scores for variables in ADNC-treated tendons were significantly improved, compared with scores for control tendons, including better orga-

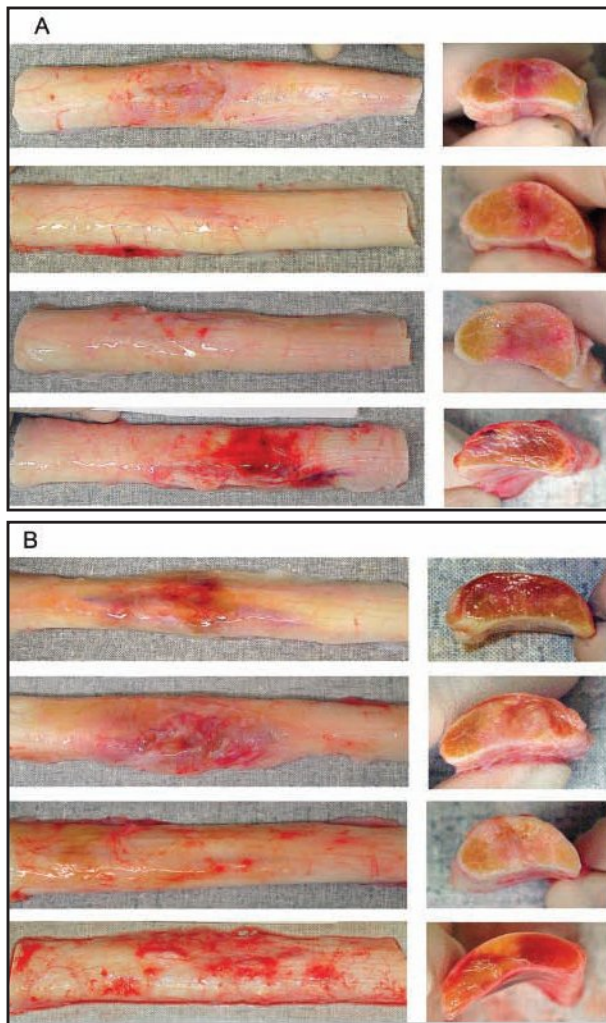


Figure 1—Photographs of longitudinal and cross-sectional tissue sections of SDFTs obtained from horses with collagenase-induced tendinitis. Seven days after collagenase injection, horses were treated by injection with ADNCs (A) or PBS solution (B). Horses were euthanized, and SDFTs were obtained 42 days after injection of ADNCs or PBS solution.



Figure 2—Ultrasonographic results for lesion size (A), linear fiber pattern (B), and lesion grade (C) in SDFTs after injection with PBS solution (control [circles]) or autologous ADNCs (triangles). Results were determined by serial ultrasonographic examination of each group (4 horses/group). Collagenase was injected to induce tendinitis. Seven days later, PBS solution or ADNC treatments were injected (day 0). Lesion size represents the percentage of the lesion size, compared with the lesion size on day 0. Lesion grade was scored on a scale from 1 (normal tendon) to 4 (extensive damage). Linear fiber pattern was graded on a scale from 1 to 4 (1 = loss of 0% to 25%, 2 = loss of > 25% to 50%, 3 = loss of > 50% to 75%, and 4 = loss of > 75% to 100%).

nization of tendon fibers ( $P = 0.08$ ) and reduced WBC infiltrates ( $P = 0.03$ ). Significant improvement in scores for organization of tendon fiber, which comprised linearity of collagen fibers, uniformity, and crimp and cocrimp appearances for polarized light microscopy, was evident in ADNC-injected tendons (mean,  $1.79 \pm 0.6$ ), compared with scores for control tendons ( $2.79 \pm 0.4$ ; Figure 3). Loss of cross linking of collagen fibers was apparent in the central bundles of tendon fibers from ADNC-injected SDFTs. Improvements in uniformity of collagen fibers and crimping appearances were apparent during polarized light microscopy of sections stained with picosirius red F3B stain (Figure 4).

**Immunohistochemical analysis for collagen**—Distribution of collagen type I and type III among longitudinal sections of tendon was scored; these data were included in the composite score for histologic grading. There were no apparent differences in proliferation or

spatial arrangement of collagen type I within ADNC-injected or control tendons. Formation of collagen type III in ADNC-treated tendons was reduced throughout the tendon sections, with concentrations around residual regions that had higher cellularity, which also coincided with decreases in crimping and cocrimping of collagen fibers (Figure 5).

**Expression of collagen mRNA**—Collagen gene expression by cells in the tendons was assessed by in situ localization of collagen type I and type III mRNA. Expression of collagen type I was increased in areas of endotenon proliferation within each section and in the epitenon. Apparent differences were not evident between ADNC-treated and control tendons. Expression of collagen type III




Figure 3—Photomicrographs of tissue sections of SDFT from representative horses obtained 42 days after injection of PBS solution (A and B) or ADNCs (C and D). Sections were stained with H&E and examined by use of light microscopy (A and C) and polarized light microscopy (B and D) to reveal organization of tendon fibers. Bar = 100  $\mu$ m.

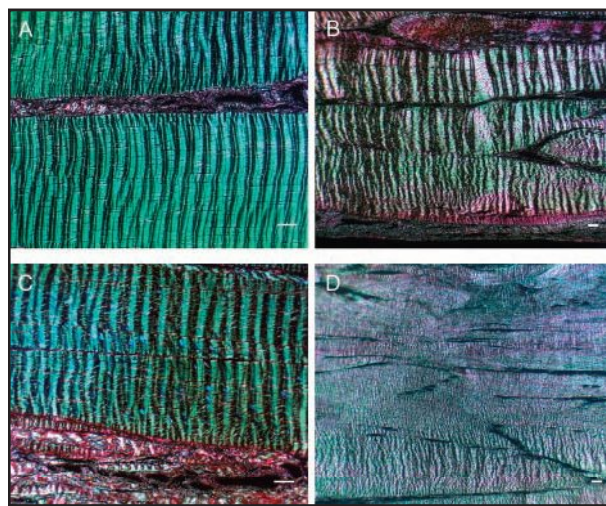


Figure 4—Photomicrographs of tendon sections from SDFTs injected with ADNCs (A and B) and PBS solution (C and D) and examined by use of polarized light microscopy. Note the periodicity for crimp of the tendon fibers and cocrimp organization. The edge of each lesion (A and C) has a more normal coarse crimp and cocrimping, whereas the center of each lesion (B and D) has better crimp formation in the ADNC-injected tendons (B). Picosirius red F3B stain. Bar = 100  $\mu$ m.




Figure 5—Photomicrographs of collagen type III immunoreactivity in tissue sections of representative SDFT samples obtained from 3 horses injected with PBS solution (A through D) or ADNCs (E through H). Control sections (D and H) resulted from application of nonimmune serum to serial sections. Collagen type III has formed throughout all sections, and intense deposition of collagen type III is apparent throughout bundles of tendon fibers in tendons injected with PBS solution (A through C). Reaction used primary antibodies against collagen type III and biotinylated secondary antibodies; diaminobenzidine tetrachloride chromogen; counterstained with hematoxylin. Bar = 100  $\mu$ m.

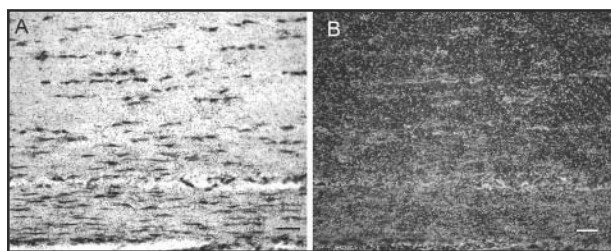


Figure 6—Photomicrographs of expression of IGF-1 mRNA in tissue sections of tendons obtained from representative horses injected with ADNCs and examined by use of bright-field microscopy (A) and dark-field microscopy (B). Active IGF-1 mRNA expression is evident in tenocytes and intervening endotenon layers. In situ IGF-1 gene expression was identified by use of equine-specific [<sup>35</sup>S]-uridine triphosphate-labeled antisense probes, with hematoxylin counterstain. Bar = 25  $\mu$ m.

Table 1—Gene expression of tendon matrix molecules measured by use of fluorescence-based real-time PCR assay in healing SDFTs obtained 42 days after injection of horses with PBS solution (control group; n = 4) or autogenous ADNCs (4).

Treatment	Collagen type I	Collagen type III	Decorin	COMP
Control	11.78 $\pm$ 3.73	14.70 $\pm$ 4.62	9.57 $\pm$ 2.30	1.10 $\pm$ 0.48
ADNC	11.98 $\pm$ 1.95	15.38 $\pm$ 2.79	7.62 $\pm$ 3.27	2.33 $\pm$ 0.64*

Results represent mean  $\pm$  SD absolute copy number  $\times 10^4$ ; copy numbers were adjusted on the basis of expression of 18S RNA used as a housekeeping gene.  
\*Within a column, value differs significantly ( $P < 0.05$ ) from the value for the control group.

Table 2—Biochemical composition of healing SDFTs obtained 42 days after injection of horses with PBS solution (control group; n = 4) or autogenous ADNCs (4).

Treatment	DNA ( $\mu$ g/mg)	Glycosaminoglycan ( $\mu$ g/mg)	Collagen ( $\mu$ g/mg)
Control	2.09 $\pm$ 0.46	21.52 $\pm$ 7.25	617.40 $\pm$ 34.55
ADNC	1.73 $\pm$ 0.27	20.76 $\pm$ 7.76	612.12 $\pm$ 56.63

Results are mean  $\pm$  SD and were standardized per milligram of tendon tissue (dry-weight basis).

was evident in areas of tendon healing and was reduced in ADNC-treated tendons. Combined histologic scores for collagen type III mRNA and collagen deposition revealed significant ( $P = 0.03$ ) improvement in ADNC-injected tendons (mean  $\pm$  SD, 2.13  $\pm$  0.48), compared with scores for control tendons (3.13  $\pm$  0.25).

**Expression of IGF-1**—To evaluate other reasons for the improvement in structural organization of ADNC-treated tendons, spatial expression of IGF-1 was assessed by use of in situ hybridization. Expression of IGF-1 was evident at similar intensity and distribution throughout tendon sections from ADNC-treated and control tendons. Expression was evident in tenocytes as well as endotenon layers (Figure 6). Scores for expression of IGF-1 in sections from ADNC-treated and control tendons were similar.

**Expression of matrix genes**—Gene expression for decorin and collagen type I and type III was not significantly different between groups (Table 1). Expression for COMP was significantly ( $P = 0.022$ ) increased in the ADNC-treated group, compared with expression for the control group.

**Biochemical assessment**—The DNA content, glycosaminoglycan content, and content of total soluble collagen did not differ significantly between ADNC-treated and control tendons (Table 2).

## Discussion

Intralesional injection of isolated ADNCs during healing of tendinitis in the SDFT improved the outcome for tendon structure. The short-term study reported here was designed to assess the immediate impact of injection of multipotent cells into an acute tendinitis lesion. Assay of DNA content and scoring of cell density during histologic examination suggested that ADNC injection had little impact on overall cell number. Rather, the principal effect appeared to be an anti-inflammatory benefit and improvement in structural organization in the healing tendon. Semiquantitative morphologic indices for collagen organization and tendon fiber architecture revealed improvement, and in combination with a reduction in inflammatory cell infiltrate, the composite histologic scores for ADNC-injected tendons were superior to those for control tendons injected with PBS solution. Both MSCs and adipose tissue-derived stem cells have immunosuppressive effects,<sup>58,59</sup> and the stem cell component (as well as potentially other cell types) within ADNC injections may reduce local tissue inflammation.

Surgical harvest of adipose tissue was technically simple. When horses were particularly lean, adequate samples of adipose tissue were obtained via bilateral access to the dorsal gluteal region. Digestion of the adipose tissues, separation of the lipid, and concentration of the remaining nucleated cells provided the injectable product. The technical aspects of limited incision and dissection of subcutaneous adipose tissues were slightly more complex than those for aspiration of bone marrow from the sternum or tuber coxa. However, the ADNC product differs from bone marrow aspirate. Digestion and centrifugation of ADNC and removal of lipid from the adipose sample results in a concentrated cell mass, compared with the predominantly blood-diluted constituents of a bone marrow aspirate. Achieving higher cell numbers from marrow requires propagation of the adherent population over a period of several weeks, which does not compare favorably with the short interval for generation of a nucleated cell pool following digestion of adipose tissue.<sup>22,25</sup> Additionally, regulatory authorities (eg, the FDA Center for Veterinary Medicine) allow autologous minimally manipulated cell therapy in horses when the procedures do not appreciably change the cells (ie, differentiation), whereas more manipulative methods, such as culture, differentiation, or sorting, may require formal approval as a drug before clinical use, which would add another dimension to the choice of treatment.

Impact of the various cell types in adipose tissue digests and bone marrow aspirates are largely unknown.<sup>60</sup> Furthermore, the value or necessity for isolating and proliferating specific adherent cell lines from each tissue source, and the impact of additional growth factors contained in bone marrow and at unknown quantities in adipose tissue or digested derivatives, are poorly understood. Harvest of multipotent cells from adipose tissue and bone

marrow aspirates results in a heterogeneous population of nucleated cells.<sup>35</sup> Use of limited enzymatic digestion of adipose tissue and collection of all nucleated cells broadens the heterogeneity of cell types to include endothelial cells, fibroblastic cells, pericytes, smooth muscle cells, macrophages, and other formed nucleated blood cells.<sup>30</sup> It is not apparent from the literature which of these lineages is potentially stimulatory to tendon healing. However, at a minimum, pericytes are multipotent and may contribute to the local tenocyte population.<sup>53,61</sup> Other studies<sup>30,39,62</sup> have revealed that approximately 80% of the cells isolated from human lipid aspirates are mesenchymal in origin and, when provided with appropriate *in vitro* factors, can differentiate into adipose tissue, bone, cartilage, muscle, and nerve cell lineages.

Use of adult tissue-derived stem cells to enhance healing of connective tissue may provide more than cells alone. Interest has been directed at the anti-inflammatory, antiapoptotic, and growth factor stimulatory aspects of injection with multipotent cell mixtures.<sup>58,59,63</sup> For tendon healing, a combination of anti-inflammatory effects and bolstered cell numbers may minimize the breakdown of propagating collagen fibers that result from the original injury. Moreover, the addition of growth factors active in enhancing vascular ingrowth, particularly vascular endothelial growth factor, may play a role in revascularization of the poorly viable core lesion within tendinitis regions in horses.<sup>64,65</sup> The role and temporal sequence characteristics of growth factors and other bioactive peptides in tendon injury and the acute phase of healing have been defined only for a few growth factors.<sup>50</sup> Injection of ADNCs has the propensity to provide anti-inflammatory effects,<sup>58,59</sup> add bioactive peptides, and potentially transplant a multipotent cell pool that can contribute to reformation and architectural organization of tendon fibers. Results of the study reported here suggest that the effect of ADNCs may be more in maintaining or inducing organized tendon architecture, rather than in provision of an increased pool of cells to participate in the healing response. Additionally, although DNA content was similar in treated and control tendons, ADNC-injected tendons had a reduction in inflammatory cells within the lesion, which suggests that other cell populations (such as endotenon and tenocyte layers) may be enhanced in ADNC-treated repair of tendons. This contradicts a study<sup>66</sup> of MSC effects on repair of patellar tendons in rabbits in which the investigators concluded that improvements in mechanical capabilities were not attributable to improvements in tendon organization. However, that study in rabbits did not include DNA data or histomorphometric quantitation of cell numbers, and few legitimate comparisons can be made with results for our study. However, without labeling of the autologous ADNCs prior to injection, the study reported here lacks specific information on cell survival to enable us to characterize cell persistence and the impact on tendon repair.

Expression of COMP was significantly increased in the ADNC-injected tendons. Originally identified in cartilage, COMP is a noncollagenous glycoprotein that provides structural integrity to the extracellular matrix by binding to multiple collagen fibrils. It may play a role in promoting formation of collagen fibrils, which could po-

tentially influence the quality of tendon and integrity of cartilage matrix.<sup>67,68</sup> Concentrations of COMP in equine digital flexor tendons are positively correlated with ultimate tensile strength and stiffness, which suggests that COMP concentrations may be linked to organization of the tendon matrix.<sup>69,70</sup> An increase in expression of COMP mRNA in the ADNC-treated tendons was consistent with the histologic evidence of improvements in tendon architecture and may be indicative of improvements in tendon regeneration, or at the least, reductions in degeneration of tendon fibers as a result of ADNC treatment. This may be particularly relevant because analysis of COMP concentrations in synovial fluid, tendon sheath fluid, and plasma are influenced considerably more by tissue heterogeneity than COMP concentrations in this focal tendinitis repair site.

Tendons injected with ADNCs had reductions in inflammatory cell infiltrate. This suggested that ADNCs may have had an anti-inflammatory effect on the regenerating tendon or may have had some other anti-inflammatory effect through stabilizing or minimizing ongoing degeneration of tendon fibers. The mechanism for the ADNC anti-inflammatory effects are largely unknown, and the combination of an anti-inflammatory effect, discrete antiapoptotic effects, and recruitment of additional local multipotent stem cell pools to contribute to tendon healing are all possible.<sup>27</sup> These mechanisms likely contributed to the reduction in tissue inflammation and improvements in tendon fiber architecture detected in the ADNC-treated tendons.

Adipose tissue provided a source of cells that appeared to contribute to tendon repair in various ways. Isolation of an injectable cell pool derived from adipose tissue provided distinct advantages with regard to timeliness, compared with the time frame for cultured multipotent stem cells derived from other tissue sources. Cost savings as a result of the reduction in the interval from tissue collection until cell injection, simplicity of laboratory procedures, and potential for a bioactive mixture of cells and intrinsic peptides provided additional advantages, compared with use of an injection of cultured MSCs.<sup>71</sup> Morbidity associated with harvest of adipose tissue was mild, cell yield was high, and the interval from tissue harvest until injection of the cellular product was minimal, compared with results for cultured MSCs derived from bone marrow.<sup>22,25</sup> The improvements in overall histologic appearance of the tendon tissue and gene expression of a glycoprotein that correlated with organized mature tendon tissue were important variables for assessment of tendon repair. The short-term morphologic results for the study support the need for long-term studies and potential clinical trials of ADNCs for the treatment of horses with tendon injuries.

- a. Birch HL. *An investigation into the cellular basis of tendon degeneration*. Doctoral thesis, Department of Anatomy, School of Veterinary Science, University of Bristol, Bristol, England, 1993.
- b. Sigma-Aldrich Co, St Louis, Mo.
- c. ATL-HDI 5000 ultrasound, Philips Medical Systems, Bothell, Wash.
- d. Vet-Stem Inc, Poway, Calif.
- e. Complete miniprotease inhibitors, Roche Molecular Biochemicals, Mannheim, Germany.
- f. NTB-2, Eastman Kodak, Rochester, NY.
- g. Biogenex, San Ramon, Calif.
- h. 6750 Spex Mill, Spex Certiprep, Metuchen, NJ.



- i. Gibco-Life Technologies, Grand Island, NY.
- j. RNeasy, Qiagen, Valencia, Calif.
- k. TaqMan 7900 HT, Applied Biosystems, Foster City, Calif.
- l. Primer Express software, version 2.0, Applied Biosystems, Foster City, Calif.
- m. Sircol assay, Biocolor Ltd, Belfast, Northern Ireland.
- n. Igepal-CA630, Sigma-Aldrich Co, St Louis, Mo.

## References

1. Kasashima Y, Takahashi T, Smith RK, et al. Prevalence of superficial digital flexor tendonitis and suspensory desmitis in Japanese Thoroughbred flat racehorses in 1999. *Equine Vet J* 2004;36:346–350.
2. Rosedale PD, Hopes R, Wingfield-Digby NJ, et al. Epidemiological study of wastage among racehorses in 1982 and 1983. *Vet Rec* 1985;116:66–69.
3. Goodship AE, Birch HL, Wilson AM. The pathobiology and repair of tendon and ligament injury. *Vet Clin North Am Equine Pract* 1994;10:323–349.
4. Genovese RL. Prognosis of superficial flexor tendon and suspensory ligament injuries, in *Proceedings*. 39th Annu Conv Am Assoc Equine Pract 1993;17–19.
5. Rooney JR, Genovese RL. A survey and analysis of bowed tendon in Thoroughbred racehorses. *Equine Vet Sci* 1981;1:49–53.
6. Dyson SJ. Treatment of superficial digital flexor tendinitis: a comparison of conservative management, sodium hyaluronate, and glycosaminoglycan polysulfate, in *Proceedings*. 43rd Annu Conv Am Assoc Equine Pract 1997;297–300.
7. Dyson SJ. Medical management of superficial digital flexor tendonitis: a comparative study in 219 horses (1992–2000). *Equine Vet J* 2004;36:415–419.
8. Bramlage LR, Hogan PM. Career results of 137 Thoroughbred racehorses that have undergone superior check ligament desmotomy for treatment of tendinitis, in *Proceedings*. 42nd Annu Conv Am Assoc Equine Pract 1996;162–163.
9. Foland J, Trotter GW, Powers BE, et al. Effect of sodium hyaluronate in collagenase-induced superficial digital flexor tendinitis in horses. *Am J Vet Res* 1992;53:2371–2376.
10. Gaughan EM, Gift LJ, De Bowes RM, et al. The influence of sequential intratendinous sodium hyaluronate on tendon healing in horses. *Vet Comp Orthop Traumatol* 1995;8:40–45.
11. Gift LJ, Gaughan EM, DeBowes RM, et al. The influence of intratendinous sodium hyaluronate on tendon healing in horses. *Vet Comp Orthop Traumatol* 1992;4:151–157.
12. Henninger RW, Bramlage LR, Bailey M, et al. Effects of tendon splitting on experimentally-induced acute equine tendinitis. *Vet Comp Orthop Traumatol* 1992;5:1–9.
13. Ferraro GL. Lameness diagnosis and treatment in the Thoroughbred racehorse. *Vet Clin North Am Equine Pract* 1990;6:63–84.
14. Gillis C. Tendon and ligament rehabilitation, in *Proceedings*. Dubai Int Equine Symp 1996;417–421.
15. Hogan PM, Bramlage LR. Transection of the accessory ligament of the superficial digital flexor tendon for treatment of tendinitis: long term results in 61 Standardbred racehorses (1985–1992). *Equine Vet J* 1995;27:221–226.
16. Fulton IC, Maclean AA, O'Reilly JL, et al. Superior check ligament desmotomy for treatment of superficial digital flexor tendonitis in Thoroughbred and Standardbred horses. *Aust Vet J* 1994;71:233–235.
17. Stashak TS. Management of wounds associated with tendons, paratendons, and tendon sheaths. In: Stashak TS, ed. *Equine wound management*. Philadelphia: Lea & Febiger, 1991;238–257.
18. Murphy DJ, Nixon AJ. Biochemical and site-specific effects of insulin-like growth factor I on intrinsic tenocyte activity in equine flexor tendons. *Am J Vet Res* 1997;58:103–109.
19. Zaidi N, Nixon AJ. Stem cell therapy in bone repair and regeneration. *Ann N Y Acad Sci* 2007;1117:62–72.
20. Young RG, Butler DL, Weber W, et al. Use of mesenchymal stem cells in a collagen matrix for Achilles tendon repair. *J Orthop Res* 1998;16:406–413.
21. Bruder SP, Kraus KH, Goldberg VM, et al. The effect of implants loaded with autologous mesenchymal stem cells on the healing of canine segmental bone defects. *J Bone Joint Surg Am* 1998;80:985–996.
22. Smith RK, Korda M, Blunn GW, et al. Isolation and implantation of autologous equine mesenchymal stem cells from bone marrow into the superficial digital flexor tendon as a potential novel treatment. *Equine Vet J* 2003;35:99–102.
23. Di RG, Iachininoto MG, Tritarelli A, et al. Myogenic potential of adipose-tissue-derived cells. *J Cell Sci* 2006;119:2945–2952.
24. Strem BM, Hicok KC, Zhu M, et al. Multipotential differentiation of adipose tissue-derived stem cells. *Keio J Med* 2005;54:132–141.
25. Bosnakovski D, Mizuno M, Kim G, et al. Isolation and multilineage differentiation of bovine bone marrow mesenchymal stem cells. *Cell Tissue Res* 2005;319:243–253.
26. Baksh D, Song L, Tuan RS. Adult mesenchymal stem cells: characterization, differentiation, and application in cell and gene therapy. *J Cell Mol Med* 2004;8:301–316.
27. Caplan AI. Review: mesenchymal stem cells: cell-based reconstructive therapy in orthopedics. *Tissue Eng* 2005;11:1198–1211.
28. Grove JE, Bruscia E, Krause DS. Plasticity of bone marrow-derived stem cells. *Stem Cells* 2004;22:487–500.
29. Prockop DJ. Marrow stromal cells as stem cells for nonhematopoietic tissues. *Science* 1997;276:71–74.
30. Zuk PA, Benhaim P, Hedrick MH. Stem cells from adipose tissue. In: Lanzer R, Blau H, Melton D, et al, eds. *Handbook of stem cells. Volume 2. Adult and fetal stem cells*. New York: Academic Press Inc, 2004;425–447.
31. Bi Y, Ehrichou D, Kilts TM, et al. Identification of tendon stem/progenitor cells and the role of the extracellular matrix in their niche. *Nat Med* 2007;13:1219–1227.
32. Friedenstein AJ, Petrakova KV, Kurolesova AI, et al. Heterotopic transplants of bone marrow. Analysis of precursor cells for osteogenic and hematopoietic tissues. *Transplantation* 1968;6:230–247.
33. Zuk PA. Stem cell research has only just begun. *Science* 2001;293:211–212.
34. Durando MM, Zarucco L, Schaer TP, et al. Pneumopericardium in a horse secondary to sternal bone marrow aspiration. *Equine Vet Educ* 2006;2:75–79.
35. Fortier LA, Nixon AJ, Williams J, et al. Isolation and chondrocytic differentiation of equine bone marrow-derived mesenchymal stem cells. *Am J Vet Res* 1998;59:1182–1187.
36. Wilke MM, Nydam D, Nixon AJ. Enhanced early chondrogenesis in articular defects following arthroscopic mesenchymal stem cell implantation in an equine model. *J Orthop Res* 2007;25:913–925.
37. Herthel DJ. Enhanced suspensory ligament healing in 100 horses by stem cell and other bone marrow components, in *Proceedings*. 47th Annu Conv Am Assoc Equine Pract 2001;319–321.
38. Smith RK, Webbon PM. Harnessing the stem cell for the treatment of tendon injuries: heralding a new dawn? *Br J Sports Med* 2005;39:582–584.
39. Strem BM, Hedrick MH. The growing importance of fat in regenerative medicine. *Trends Biotechnol* 2005;23:64–66.
40. Zuk PA, Zhu M, Ashjian P, et al. Human adipose tissue is a source of multipotent stem cells. *Mol Biol Cell* 2002;13:4279–4295.
41. Fraser JK, Wulur I, Alfonso Z, et al. Fat tissue: an underappreciated source of stem cells for biotechnology. *Trends Biotechnol* 2006;24:150–154.
42. Nathan S, Das DS, Thambyah A, et al. Cell-based therapy in the repair of osteochondral defects: a novel use for adipose tissue. *Tissue Eng* 2003;9:733–744.
43. Cowan CM, Shi YY, Aalami OO, et al. Adipose-derived adult stromal cells heal critical-size mouse calvarial defects. *Nat Biotechnol* 2004;22:560–567.
44. Rehman J, Traktuev D, Li J, et al. Secretion of angiogenic and antiapoptotic factors by human adipose stromal cells. *Circulation* 2004;109:1292–1298.
45. Williams IF, McCullagh GD, Goodship AE, et al. Studies on the pathogenesis of equine tendinitis following collagenase injury. *Res Vet Sci* 1984;36:326–338.
46. Redding WR, Booth LC, Pool RR. The effects of polysulphated glycosaminoglycan on the healing of collagenase-induced tendinitis. *Vet Comp Orthop Traumatol* 1999;12:48–55.
47. Keg PR, van den Belt AJM, Merckens HW, et al. The effect of regional nerve blocks on the lameness caused by collagenase induced tendonitis in the midmetacarpal region of the horse: a study using gait analysis and ultrasonography to determine tendon healing. *Zentralbl Veterinarmed A* 1992;39:349–364.

48. Dowling BA, Dart AJ, Hodgson DR, et al. The effect of recombinant equine growth hormone on the biomechanical properties of healing superficial digital flexor tendons in horses. *Vet Surg* 2002;31:320–324.
49. Dahlgren LA, Brower-Toland BD, Nixon AJ. Cloning and expression of type III collagen in normal and injured tendons of horses. *Am J Vet Res* 2005;66:266–270.
50. Dahlgren LA, Mohammed HO, Nixon AJ. Temporal expression of growth factors and matrix molecules in healing tendon lesions. *J Orthop Res* 2005;23:84–92.
51. Dahlgren LA, van der Meulen MC, Bertram JE, et al. Insulin-like growth factor-I improves cellular and molecular aspects of healing in a collagenase-induced model of flexor tendinitis. *J Orthop Res* 2002;20:910–919.
52. Reef VB. Musculoskeletal ultrasonography. In: Reef VB, ed. *Equine diagnostic ultrasound*. Philadelphia: WB Saunders Co, 1998;39–186.
53. Zuk PA, Zhu M, Mizuno H, et al. Multilineage cells from human adipose tissue: implications for cell-based therapies. *Tissue Eng* 2001;7:211–228.
54. Goodrich LR, Hidaka C, Robbins PD, et al. Genetic modification of chondrocytes with insulin-like growth factor-1 enhances cartilage healing in an equine model. *J Bone Joint Surg Br* 2007;89:672–685.
55. Nixon AJ, Haupt JL, Frisbie DD, et al. Gene mediated restoration of cartilage matrix by combination insulin-like growth factor-I/interleukin-1 receptor antagonist therapy. *Gene Ther* 2005;12:177–186.
56. Farndale RW, Buttle DJ, Barrett AJ. Improved quantitation and discrimination of sulphated glycosaminoglycans by use of dimethylmethylene blue. *Biochim Biophys Acta* 1986;883:173–177.
57. Kim Y-J, Sah RLY, Doong J-YH, et al. Fluorometric assay of DNA in cartilage explants using Hoechst 33258. *Anal Biochem* 1988;174:168–176.
58. Puissant B, Barreau C, Bourin P, et al. Immunomodulatory effect of human adipose tissue-derived adult stem cells: comparison with bone marrow mesenchymal stem cells. *Br J Haematol* 2005;129:118–129.
59. Wolbank S, Peterbauer A, Fahrner M, et al. Dose-dependent immunomodulatory effect of human stem cells from amniotic membrane: a comparison with human mesenchymal stem cells from adipose tissue. *Tissue Eng* 2007;13:1173–1183.
60. Butler DL, Juncosa-Melvin N, Boivin GP, et al. Functional tissue engineering for tendon repair: A multidisciplinary strategy using mesenchymal stem cells, bioscaffolds, and mechanical stimulation. *J Orthop Res* 2008;26:1–9.
61. Diefenderfer DL, Brighton CT. Microvascular pericytes express aggrecan message which is regulated by BMP-2. *Biochem Biophys Res Commun* 2000;269:172–178.
62. Lin Y, Chen X, Yan Z, et al. Multilineage differentiation of adipose-derived stromal cells from GFP transgenic mice. *Mol Cell Biochem* 2006;285:69–78.
63. Fang B, Song YP, Liao LM, et al. Treatment of severe therapy-resistant acute graft-versus-host disease with human adipose tissue-derived mesenchymal stem cells. *Bone Marrow Transplant* 2006;38:389–390.
64. Molloy T, Wang Y, Murrell G. The roles of growth factors in tendon and ligament healing. *Sports Med* 2003;33:381–394.
65. Anitua E, Andia I, Sanchez M, et al. Autologous preparations rich in growth factors promote proliferation and induce VEGF and HGF production by human tendon cells in culture. *J Orthop Res* 2005;23:281–286.
66. Awad HA, Butler DL, Boivin GP, et al. Autologous mesenchymal stem cell-mediated repair of tendon. *Tissue Eng* 1999;5:267–277.
67. Rosenberg K, Olsson H, Morgelin M, et al. Cartilage oligomeric matrix protein shows high affinity zinc-dependent interaction with triple helical collagen. *J Biol Chem* 1998;273:20397–20403.
68. Sodersten F, Ekman S, Eloranta ML, et al. Ultrastructural immunolocalization of cartilage oligomeric matrix protein (COMP) in relation to collagen fibrils in the equine tendon. *Matrix Biol* 2005;24:376–385.
69. Smith RKW, Zunino L, Webbon PM, et al. The distribution of cartilage oligomeric matrix protein (COMP) in tendon and its variation with tendon site, age and load. *Matrix Biol* 1997;16:255–271.
70. Smith RK, Birch HL, Goodman S, et al. The influence of ageing and exercise on tendon growth and degeneration—hypotheses for the

initiation and prevention of strain-induced tendinopathies. *Comp Biochem Physiol A Mol Integr Physiol* 2002;133:1039–1050.

71. Nixon AJ. Stem cell research: where are we enhancing healing?, in *Proceedings*. 13th Annu Symp Am Coll Vet Surg 2003;1–4.

## Appendix

Histologic scoring system used for grading healing of tendon tissues in horses.

Variable	Score and criteria
Shape of tendon cells	1 = Linear (normal) 2 = Slightly oval 3 = Moderately round 4 = Predominantly round
Density of tendon cells	1 = Sparse (normal) 2 = Slight increase 3 = Moderate increase 4 = Sheets of cells
Hemorrhage	1 = None 2 = Sparse or patchy 3 = Multiple areas in each low-power field 4 = Predominant hemorrhage
Neovasculature (No. of vessels)	1 = Normal 2 = Slight increase 3 = Moderate increase 4 = Severe increase
Inflammatory cell infiltrate (leukocyte deposits in endotenon and peritenon)	1 = None 2 = Slight increase 3 = Moderate increase 4 = Severe increase
Linearity of collagen fibers	1 = Linear 2 = > 50% linear 3 = 20% to 50% linear 4 = No linear areas
Uniformity of collagen fibers	1 = Uniform diameter of all fibers 2 = > 50% of fibers are uniform 3 = 20% to 50% of fibers are uniform 4 = Complete disarray of fibers
Crimping of collagen fibers*	1 = Coarse, even crimp 2 = Predominantly fine, even crimp 3 = < 50% with crimp formation 4 = No crimp formation; complete disarray
Thickness of epitenon	1 = 1 to 2 cells (normal) 2 = 3 to 6 cells 3 = 7 to 15 cells 4 = Massive fibrosis
Collagen type I†	1 = > 90% type I 2 = > 50% to 90% type I 3 = 10% to 50% type I 4 = < 10% type I
Collagen type III‡	1 = < 10% type III 2 = 10% to 50% type III 3 = > 50% to 90% type III 4 = > 90% type III
mRNA for collagen type I†	1 = > 90% type I 2 = > 50% to 90% type I 3 = 10% to 50% type I 4 = < 10% type I
mRNA for collagen type III‡	1 = < 10% type III 2 = 10% to 50% type III 3 = > 50% to 90% type III 4 = > 90% type III

\*Determined by use of polarized light microscopy. †Determined by use of immunohistochemical analysis. ‡Determined by use of in situ hybridization.